

Implant Placement with Simultaneous Guided Bone Regeneration

Dr. Steven Faigan

Certified Specialist in Periodontics, Kelowna, British Columbia

Endosseous dental implants are a predictable modality of tooth replacement that can improve the dental health and quality of life for many people. However, there is often inadequate bone to receive and support implants. This can be the result of trauma, periodontal disease, endodontic infection, post-extraction ridge defects, disuse atrophy, etc. Therefore, guided bone regenerative procedures (GBR) have evolved to be an integral and predictable component of implant dentistry, either in preparation for, or in conjunction with, implant placement.

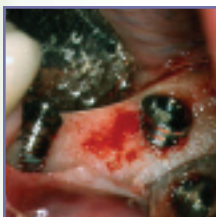

FIGURE 1

Resorption of the buccal bone

A 63 year old female patient presented requesting implants as a treatment modality to replace several missing posterior teeth in the lower left quadrant. Her natural teeth had been extracted 20 years earlier without replacement, resulting in a significant horizontal ridge deficiency. It was explained to the patient that although implants represented an ideal treatment option, it would be necessary to simultaneously augment the bone to allow for optimum bone integration and stability of the implants. The patient agreed to the proposed surgical and prosthetic treatment plan.

Two threaded, cylindrical, external hex Osseotite® implants (3i, Implant Innovations Inc., Palm Beach Gardens, FL) were placed into the areas of #20 and #18. With optimum implant positioning, and given the horizontal resorption of the host bone in the area, approximately 5-6 threads were exposed on the buccal surface of the implant in site #20 and 3-4 threads on the buccal surface of #18 (FIGURE 1).

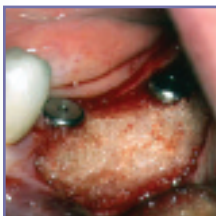

FIGURE 2

Grafted atrophic ridge

1.0 cc of DynaGraft-D™ Putty (Keystone Dental, Inc., Burlington, MA) was used to augment the deficient ridge and cover the exposed threads of the implants. DynaGraft-D™ is a bio-assayed DFDBA offering the inductive capability required to achieve regeneration of vital bone. DynaGraft-D™ comes supplied pre-mixed in a reverse phase medium allowing for ease of handling and accurate placement of the material. With simple finger manipulation, the material can be molded into the ideal three dimensional shape to augment the deficient area (FIGURE 2). Once in position, the viscosity of DynaGraft-D™ reduces the risk of dislodgement during final placement, irrigation and flap closure.

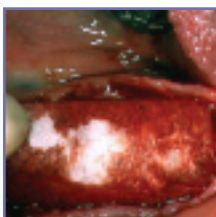


FIGURE 3

Resorbable collagen membrane

A 30x40mm Neomem™ (Citagenix Inc., Montreal, Quebec) GBR resorbable membrane was placed over the graft to assist in bone graft containment and to eliminate connective tissue and epithelial invagination into the surgical site (FIGURE 3). Re-approximation of the flaps was achieved and tension free primary closure established utilizing 5-0 chromic gut sutures. A two stage submerged protocol was undertaken given the simultaneous GBR procedure.

(continued)

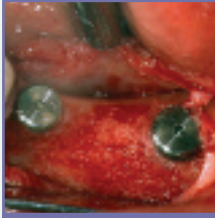


FIGURE 4
Regeneration of bone

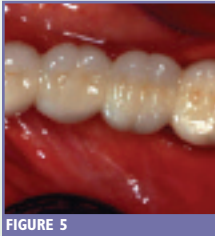

FIGURE 5
Final restoration

Healing was uneventful and the implants were uncovered at 9 months. Clinical evaluation confirmed the apparent regeneration of bone on the buccal aspect of the mandible with coverage of the exposed implants threads (FIGURE 4). At this time, the implants were stable and integrated and 3i's emergence profile transitional healing abutments were placed. A soft tissue healing period followed for the next 6 weeks. Prefabricated, preparable GingiHue™ Post (3i) prosthetic abutments were inserted and the patient restored with a ceramo-metal cemented fixed bridge (FIGURE 5).

Without the assistance of augmentation materials, endosseous implants would be limited to only those patients that presented with alveolar ridges with adequate bone volume. The predictability of guided bone regeneration techniques has increased the number of implant candidates and has facilitated prosthetically driven restorations.